



Creative solutions

Rapid progress in medical care is constantly being challenged by a situation of escalating healthcare costs but finite resources. To provide safe and effective healthcare delivery within the realities of economic constraints, we need to explore initiatives that provide such healthcare at an affordable cost. Here, *Oncology Exchange* profiles an innovative experience at Toronto Western Hospital with outpatient surgery for brain tumour patients. Logistics and the feasibility of this approach are presented for 2 groups of patients: those needing stereotactic surgery for brain biopsy and those needing craniotomy.

Mark Bernstein, MD, MHSc, FRCSC is Professor of Surgery at the University of Toronto and a neurosurgeon at Toronto Western Hospital, University Health Network.

Address for correspondence: Division of Neurosurgery, Toronto Western Hospital, University Health Network, 399 Bathurst Street, 4W451, Toronto, ON M5T 2S8, Tel: (416) 603-6499; Fax: (416) 603-5298; Email: mark.bernstein@uhn.on.ca

OUTPATIENT BRAIN TUMOUR SURGERY

A new paradigm in healthcare delivery

Mark Bernstein, MD, MHSc, FRCSC

Initiatives like outpatient surgery have evolved as alternative approaches in healthcare delivery, even in the realm of complex specialties like neurosurgery.^{1,2} This is particularly important in the Canadian context, with a healthcare system that is publicly funded and not-for-profit.

GROUNDWORK

For successful implementation of outpatient surgery, a carefully planned infrastructure is essential to integrate activities between healthcare providers, patients and payers. The Institute of Medicine (U.S.) suggests 6 dimensions for evaluating health system performance: safety, effectiveness, patient-centredness, timeliness, efficiency and equity.³ Conrad has further examined these in the context of ambulatory (i.e. outpatient) surgery and specifically focused on 2 aspects of operational efficacy in healthcare: technical competence and allocative efficiency.⁴

Patients have concerns related to uncertainty about what to expect after surgery, pain management and facilities for postoperative care.⁵ Several studies demonstrate that provision of adequate information by healthcare providers through verbal, audiovisual and printed materials significantly reduces anxiety.⁵⁻⁹ The potential input of allied healthcare professionals, especially nurses, is also paramount to the success of outpatient surgery, e.g. for assessing patients' concerns, preparing and disseminating information, and post-surgical home visits.¹⁰

OUTPATIENT STEREOTACTIC SURGERY

Stereotactic surgery involves accurate localization of an intracranial target using a special frame fixed to the patient's head, a preoperative imaging study and dedicated computer software. The most common applications in oncology are to biopsy tumours felt to be inappropriate for resection and to facilitate accurate insertion of Ommaya reservoir for intrathecal chemotherapy administration. Standard care following such procedures entails overnight observation.

Protocol

Between August 1996 and August 2004, we performed 132 stereotactic surgeries at Toronto Western Hospital on an ambulatory basis including 105 brain tumour biopsies, mostly for gliomas, and insertion of 27 Ommaya reservoirs. This represented 46% of the 288 cranial stereotactic procedures carried out during that time. Patients eligible for outpatient surgery are not already hospital inpatients, have no significant medical comorbidities or incapacitating neurologic deficits, and live with responsible adults capable of recognizing a change in the patient's neurologic status. Outpatient surgery is not done on those who live far away from the hospital or who express a preference for inpatient treatment.

After admission to the Day Surgery Unit (DSU) the morning of surgery, the stereotactic base ring and localizer of the stereotactic frame are applied to the patient's head and a CT or MRI visualizes the tumour, with the desired target for biopsy. A guiding arc system then replaces the localizer ring. A stereotactic biopsy or insertion of Ommaya reservoir is performed in the operating room under local and light neurolept anesthesia (**Figure 1**).

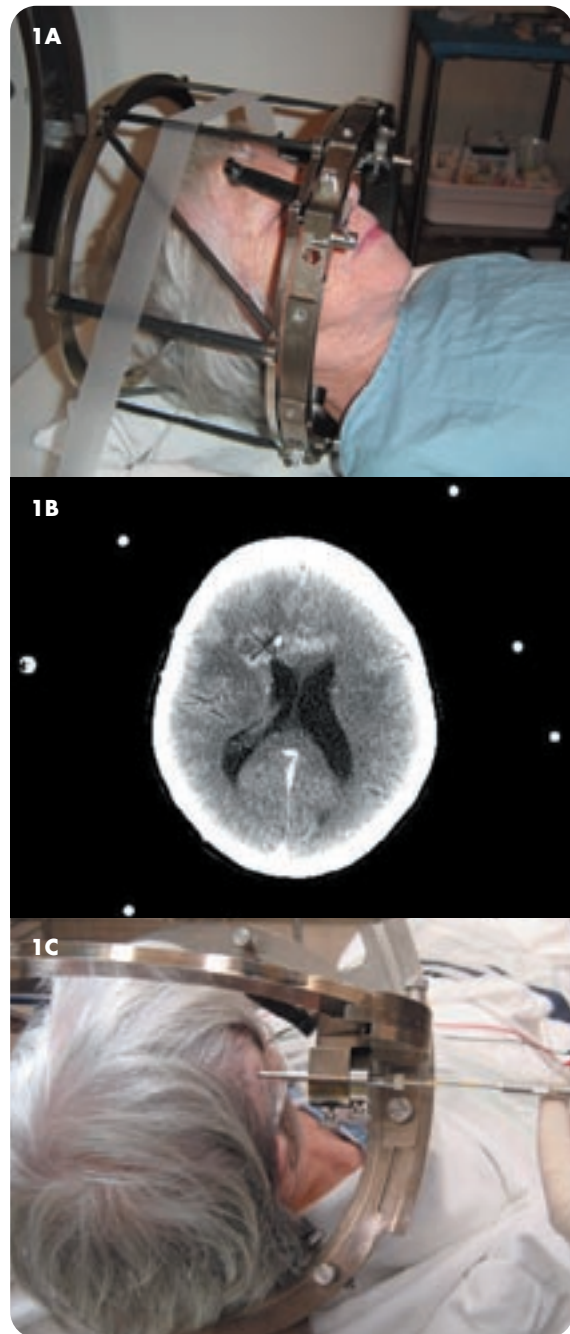
After surgery the patient is monitored in the Post Anesthetic Care Unit (PACU) for 2 hours and then in the DSU for another 4 hours. Postoperative CT scan is reserved for patients who experience persistent headache or neurologic deterioration. The neurosurgeon examines the patient in the DSU to assess fitness for discharge and provides a prescription for analgesics and documents, e.g. information on wound care, advice about diet and activity, and instructions about followup. Patients are currently discharged 6 hours following surgery. A homecare nurse visits in the evening and the neurosurgeon sees the patient 10 days later for discussion of the final pathology and to plan further treatment.

Outcomes

Of the 132 patients entered in the ambulatory protocol, 126 (95.5%) successfully completed it and 6 required admission. We conservatively estimated cost savings of \$1140 (Canadian) per patient, compared to inpatient stereotactic biopsy.²

Perceived risk of intracerebral hemorrhage developing after discharge has impeded wide implementation of outpatient stereotactic surgery in most centres. Evidence suggests that the timing of occurrence of clinically significant hematoma is quite predictable and that most occur within a few hours of surgery. In a series of 2305 craniotomies and stereotactic surgeries Taylor et al recorded 50 cases of postoperative hematoma: all presented clinically either within 6 hours (44 patients) or after 24 hours (6 patients).¹¹ After supratentorial brain biopsy specifically, conflicting arguments have been made regarding postoperative hemorrhage and subsequent risk of delayed neurologic deterioration.¹²⁻¹⁵ Our experience involving 750 stereotactic procedures (inpatient and outpatient) has found it to be safe, with about 95.5% of patients included in the outpatient protocol being safely discharged the same day. Most importantly, not a single patient was harmed by being entered in the protocol and those with complications were identified and treated appropriately.

FIGURE 1. Stereotactic brain surgery

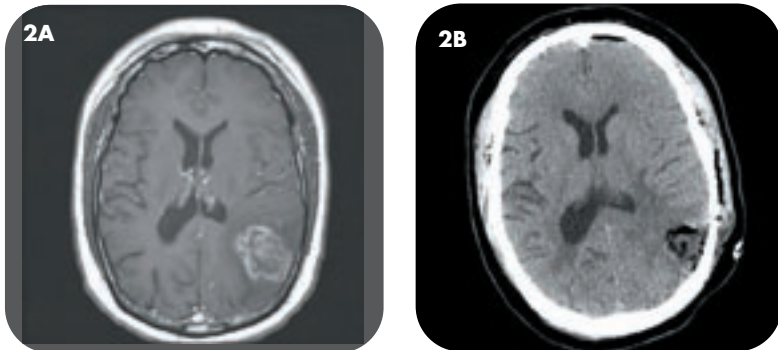


(1A) Patient with stereotactic localizer ring in CT scanner.

(1B) Enhanced CT showing corpus callosum tumour. The cursor marks the desired target for biopsy.

(1C) Intraoperative photo showing biopsy needle inserted into tumour via a twist-drill hole made under local anesthetic. The biopsy is about to be aspirated. The guiding arc system now replaces the localizer ring. Pathology revealed glioblastoma multiforme.

FIGURE 2. Pre- and postoperative MRIs of glioma



(2A) Gadolinium-enhanced axial T1-weighted MRI of 33-year-old man showing recurrent tumour 5 years after he underwent biopsy, radiation and subsequent chemotherapy for a low-grade glioma. Note significant edema surrounding tumour.

(2B) Unenhanced CT 4 hours after craniotomy for resection of the tumour and 2 hours prior to discharge on the day surgery protocol, showing a collapsed resection cavity lined with some air (black area). Patient did very well after surgery and went on to receive a new adjuvant chemotherapy regime for his anaplastic glioma.

held pointer to navigate the scalp and then the surgical field (**Figure 3**). Subsequent steps include local anesthesia, planning of the flap, craniotomy, brain mapping, intraoperative frameless navigation and microsurgical approach.^{18,19}

Following surgery, the patient is monitored in the PACU for 4 hours and then transferred to the DSU for further observation. A CT scan is routinely performed en route to the DSU. At around 6 pm, the neurosurgeon assesses fitness for discharge — absence of significant neurologic deterioration, adequate ambulation and tolerance to snacks and clear fluids — and provides appropriate prescriptions and documentation. Discharge occurs a minimum of 6 hours after surgery, with clear reminders for the patient and loved one(s) about signs and symptoms to watch for and how to contact the surgeon if needed. A homecare nurse visits at 11 pm that evening and at 8 am the following

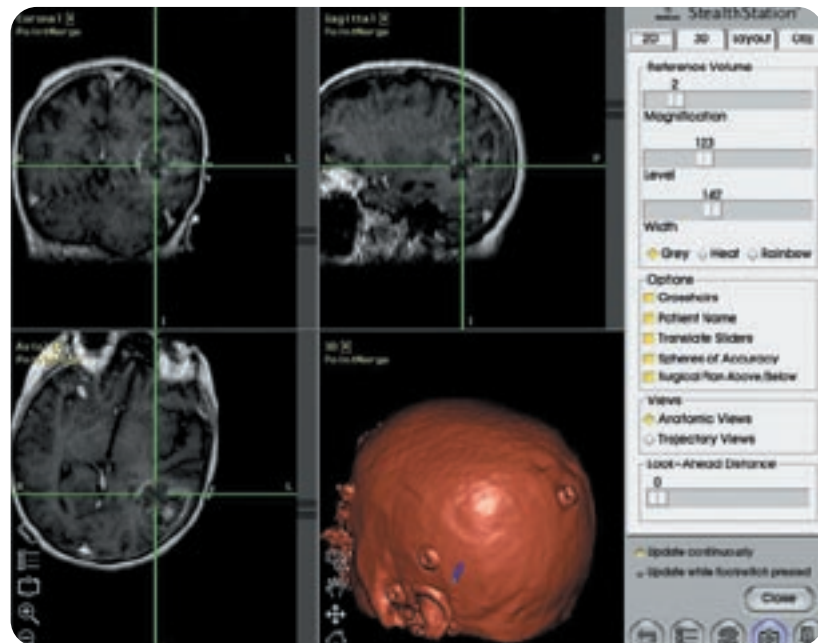
OUTPATIENT CRANIOTOMY FOR BRAIN TUMOUR

We initiated the ambulatory craniotomy project at the Toronto Western Hospital Division of Neurosurgery in November 1996, reporting the results with the first 46 patients in 2001.¹ Between 1996 and August 2004, 389 image-guided awake craniotomies were performed using either a frameless stereotactic navigation system¹⁶ or intraoperative open magnet MRI,¹⁷ and 86 (22%) of those patients were in the study cohort. Eligibility criteria are the same as for outpatient stereotactic surgery. All the patients have supratentorial intra-axial neoplasms of varying etiology (about 60% gliomas and 40% metastases), many with sizeable tumours with significant mass effect (**Figure 2**).

Procedure and followup

The protocol of preadmission workup and admission to the DSU is similar to that described above for outpatient stereotactic surgery. After admission an enhanced MRI (or CT) is done and the images are registered into the frameless navigation system, enabling the surgeon to use a hand-

FIGURE 3. Screen-save from a surgical navigation device during surgery for left parietal glioblastoma.



The cross hairs represent the tip of the hand-held pointer within the tumour relative to its position on the MRI.

morning. After 10 days the patient visits the surgeon's office for a neurologic assessment, discussion about final pathology, arrangement for adjuvant therapies and informal evaluation of level of satisfaction with the procedure.

Outcomes


Seventy-nine of 86 patients (92%) had successfully completed the outpatient craniotomy protocol by August 2004. Among these, 5 were admitted as inpatients on the same day for a variety of reasons — including 1 with neurologic deficit — and 2 were readmitted after discharge. Another 7 (8%) developed mild focal neurologic deficits not significant enough to warrant admission. No patient was harmed by the protocol and none voiced dissatisfaction.

Our experience underscores the safety, efficacy and practicality of the outpatient approach to craniotomy, however bold this may sound. In addition to good patient acceptance and obvious cost containment, we believe early mobilization and a shorter hospital stay reduces the risk of thromboembolic complications, nosocomial infections and adverse effects due to medical errors.^{20,21} For those with brain tumours such as glioblastoma multiforme, where life expectancy is measured in terms of months or years, less time spent in hospital might translate into improved quality of life, at least in the short term.

Further studies on outpatient craniotomy are required before recommending the approach as a standard neurosurgical practice. Our patient cohort study — the only one available to date — has shown, however, that it is a safe, cost-effective and feasible alternative to conventional approaches for selected patients with brain tumours.

OUTPATIENT BRAIN SURGERY — THE FUTURE?

Obstacles to outpatient stereotactic surgery include long-held beliefs about the perceived risks of these highly specialized surgeries and the reluctance of care providers to embrace innovation because of issues related to litigation. With its more predictable and lower risks of litigation than in the U.S., perhaps Canada is an excellent place for the growth of something as radical-sounding as outpatient brain tumour surgery.

Our experience has shown that outpatient stereotactic surgery and craniotomy are safe and effective options for selected patients with brain tumours, and that they are more resource-friendly than standard approaches. Certain rituals and long-held beliefs may not be in accord with reality, and in this era of evidence-based medicine we must neither decry procedures nor extol their virtues without proper evidence. Implementation of outpatient neurosurgery is not only an organizational but a social, political and cultural challenge. The time has come to embrace this new idea and others like it. 

References

- Bernstein M. Outpatient craniotomy for brain tumor: a pilot feasibility study in 46 patients. *Can J Neural Sci* 2001;28:120-24.
- Bhardwaj RD, Bernstein M. Prospective feasibility study of outpatient stereotactic brain lesion biopsy. *Neurosurgery* 2002; 51:358-61.
- Institute of Medicine. *Crossing the Quality Chasm: A New Health System for the 21st Century*. Committee on Quality Health Care in America. National Academy Press. Washington, DC, 2001.
- Conrad DA. Ambulatory care efficiency: a conceptual essay and empirical assessment. *J Ambul Care Manage* 2002;25:1-11.
- Bradshaw C, Pritchett C, Bryce C et al. Information needs of general day surgery patients. *Ambul Surg* 1999;7: 39-44.
- Brumfield VC, Kee CC, Johnson JY. Preoperative patient teaching in Ambul surg settings. *Am Oper Room Nurs J* 1996; 64:941-52.
- Mitchell M. Patient's perception of day surgery: a literature review. *Ambul Surg* 1999;7:65-73.
- Rudkin GE, Bacon AK, Burrow B et al: Review of efficiencies and patient satisfaction in Australian and New Zealand day surgery units: a pilot study. *Anaesth Intensive Care* 1996;24:74-78.
- Wallin E, Lundgren P, Ulander K, von Holstein CS. Does age, gender or educational background effect patient satisfaction with short stay surgery? *Ambul Surg* 2000;8:79-88.
- Zanchetta C, Bernstein M. The nursing role in patient education regarding outpatient neurosurgical procedures. *Axone* 2004;25:18-21.
- Taylor WA, Thomas NW, Wellings JA, Bell BA. Timing of postoperative intracranial hematoma development and implications for the best use of neurosurgical intensive care. *J Neurosurg* 1995;82:48-50.
- Kaakaji VV, Barnett GH, Bernhard D et al. Clinical and economic consequences of early discharge of patients following supratentorial stereotactic brain biopsy. *J Neurosurg* 2001;94:892-98.
- Kulkarni AV, Guha A, Lozano A, Bernstein M. Incidence of silent hemorrhage and delayed deterioration after stereotactic brain biopsy. *J Neurosurg* 1998; 89:31-35.
- Warnick RE, Longmore LM, Paul CA, Bode LA. Postoperative management of patients after stereotactic biopsy: results of a survey of the AANS/CNS section on tumors and a single institution study. *J Neurooncol* 2003;62:289-96.
- Field M, Witham TF, Flickinger JC et al. Comprehensive assessment of hemorrhage risks and outcomes after stereotactic brain biopsy. *J Neurosurg* 2001;94:545-51.
- McDermott MW. Image-guided surgery. In: *Neuro-Oncology: The Essentials* Bernstein M, Berger MS, eds. Thieme Medical Publishers, Inc. New York, 2000;135-47.
- Bernstein M, Al-Anazi A, Kucharczyk VV et al. Brain tumor surgery with the Toronto Open MRI system: preliminary results with 36 cases and analysis of advantages, weaknesses, and future prospects. *Neurosurgery* 2000;46:900-09.
- Taylor MD, Bernstein M. Awake craniotomy with brain mapping as the routine surgical approach to treating patients with supratentorial intra-axial tumours: A prospective trial of 200 cases. *J Neurosurg* 1999;90:35-41.
- Taylor MD, Bernstein M. Image-guided awake craniotomy for brain tumors. *Advances in Clinical Neurosciences* 2000;10:83-92.
- Bernstein M, Hebert PC, Etchells E. Patient safety in neurosurgery. Detection of errors, prevention of errors, and disclosure of errors. *Neurosurgery Quarterly* 2003;13:125-37.
- Baker GR, Norton PG, Flintoft V et al. The Canadian Adverse Events Study: the incidence of adverse events among hospital patients in Canada. *CMAJ* 2004;170:1678-86.